

CADAVERIC VALIDATION OF DRY NEEDLE PLACEMENT IN THE LATERAL PTERYGOID MUSCLE

Juan A. Mesa-Jiménez, PT, MSc,^{a,b} Jesús Sánchez-Gutiérrez, MD,^{c,d} José L. de-la-Hoz-Aizpurua, MD,^e and César Fernández-de-las-Peñas, PT, PhD^{f,g}

ABSTRACT

Objective: The aim of this anatomical study was to determine if a needle is able to reach the lateral pterygoid muscle during the application of dry needling technique.

Methods: A dry needling approach using 2 needles of 50 to 60 mm in length, one inserted over the zygomatic process posterior at the obituary arch (for the superior head) and other inserted below the zygomatic process between the mandibular condyle and the coronoid process (for the inferior head), was proposed. A progressive dissection into 3 stages was conducted into 2 heads of fresh male cadavers. First, dry needling of the lateral pterygoid muscle was applied on the cadaver. Second, a block dissection containing the lateral pterygoid was harvested. Finally, the ramus of the mandible was sectioned by osteotomy to visualize the lateral pterygoid muscle with the needle placements.

Results: With the needles inserted into the cadaver, the block dissection revealed that the superior needle reached the superior (sphenoid) head of the lateral pterygoid muscle and the inferior needle reached the inferior (pterygoid) head of the muscle. At the final stage of the dissection, when the ramus of the mandible was sectioned by osteotomy, it was revealed that the superior needle entered into the belly of the superior head of the lateral pterygoid muscle.

Conclusions: This anatomical study supports that dry needling technique for the lateral pterygoid muscle can be properly conducted with the proposed approach. (*J Manipulative Physiol Ther* 2014;xx:1-6)

Key Indexing Terms: *Pterygoid Muscles; Temporomandibular Joint Dysfunction Syndrome; Dry Needling*

Temporomandibular pain disorders (TMDs) include different conditions mainly characterized by pain and sometimes with joint clicking. The etiology of TMD is clearly multifactorial, although it is well accepted

that the masticatory muscles play a relevant role. One of the most important muscles related to temporomandibular joint dynamics is the lateral pterygoid muscle.

The anatomy of this muscle remains controversial. The lateral pterygoid muscle is generally subdivided into an inferior and a superior head. The inferior (pterygoid) head originates from the lateral surface of the lateral pterygoid plate, whereas the superior (sphenoid) head originates at the infratemporal surface of the sphenoid bone; however, this anatomical distinction is not very clear.¹ In fact, a study reported that the 2 heads of the muscle are not clearly divided by the positional relationships to the nerves and the sites of the origins and insertions.² Both heads converge laterally and posteriorly to their insertion into the condyle, capsule, and/or disk. As previously mentioned, the anatomical insertion of the superior head of the lateral pterygoid muscle to the articular disk is controversial. A literature review found that most anatomical studies identified 2 separate parts of the muscle as well as insertions into the disk, the capsule, and the condyle.³ However, Heylings et al⁴ found that only a small part of the superior head of the lateral pterygoid muscle is attached to the anterior portion of the capsule and firmly attached to the disk. Furthermore, Taskaya-Yilmaz et al⁵ described that lateral pterygoid muscle attachments were categorized into 2 different types: type 1, where fibers of the superior head

^a Professor, Department of Physical Therapy, Universidad San-Pablo CEU, Madrid, Spain.

^b Professor, Máster Oficial en Dolor Orofacial y Disfunción Cráneo-Mandibular, Universidad San-Pablo CEU, Madrid, Spain.

^c Clinician, Department of Maxillo-Facial Surgery, Hospital Clínico San Carlos, Madrid, Spain.

^d Professor, Máster Oficial en Dolor Orofacial y Disfunción Cráneo-Mandibular, Universidad San-Pablo CEU, Madrid, Spain.

^e Clinician, Máster Oficial en Dolor Orofacial y Disfunción Cráneo-Mandibular, Universidad San-Pablo CEU, Madrid, Spain.

^f Professor and Clinical Researcher, Department of Physical Therapy, Occupational Therapy, Physical Medicine and Rehabilitation of Universidad Rey Juan Carlos, Alcorcón, Spain.

^g Clinical Researcher, Cátedra de Investigación y Docencia en Fisioterapia, Terapia Manual y Punción Seca, Universidad Rey Juan Carlos, Alcorcón, Madrid, Spain.

Submit requests for reprints to: César Fernández-de-las-Peñas, PT, PhD, Professor and Clinical Researcher, Departamento de Fisioterapia, Facultad de Ciencias de la Salud, Universidad Rey Juan Carlos, Avenida de Atenas s/n 28922 Alcorcón, Madrid, Spain.

Paper submitted July 22, 2014; in revised form October 6, 2014; accepted October 10, 2014.

0161-4754

Copyright © 2014 by National University of Health Sciences.

<http://dx.doi.org/10.1016/j.jmpt.2014.11.004>

of the muscle were attached to the disk and fibers of the inferior head were attached to the condyle, and type 2, where fibers of the superior head of the lateral pterygoid muscle attached to the disk and condyle and fibers of the inferior head were attached to the condyle.

The clinical opinion that the lateral pterygoid muscle may be dysfunctional in patients with TMD is widely accepted. In fact, the theory of internal derangement of the temporomandibular joint involves the anterior displacement of the disk as result of hyperactivity of the lateral pterygoid muscle. From the attachment of the superior head of the muscle, it may pull the disk in an anterior and superior medial direction.⁶ For instance, patients with TMD present with some morphological alterations, that is, atrophy, hypertrophy, or contracture in the lateral pterygoid muscle.⁷ Therefore, treatment of this muscle should be considered in the management of TMD.

Palpation and, therefore, manual treatment of the lateral pterygoid muscle are under debate, and some authors claim that it is not possible owing to the topographic localization of its lower head.^{8,9} Deep dry needling (an invasive procedure where an acupuncture needle is introduced into the muscle) has been advocated as a possible therapeutic tool for the management of this muscle. Dıraçoğlu et al¹⁰ reported that point-specific dry needling was more effective than non-point-specific needling for the management of TMD. Itoh et al¹¹ found that real acupuncture treatment was more effective than sham acupuncture treatment for myofascial TMD. Finally, Gonzalez-Perez et al¹² observed that that dry needling in the lateral pterygoid muscle was effective in the management of patients with myofascial pain.

The critical importance of this muscle for TMD makes it worthwhile to develop the necessary skills for invasive treatment by dry needling. Therefore, it is important to determine the best technique to reach the lateral pterygoid muscle with a needle. To the best of the author's knowledge, no anatomical study has investigated if the needle is able to reach the lateral pterygoid muscle. Therefore, the aim of this anatomical study was to determine if the needle is able to reach the lateral pterygoid muscle during the application of dry needling.

METHODS

This study was approved by the human research committee of the Universidad Rey Juan Carlos (2013-012) and Universidad San Pablo CEU (Madrid, Spain).

Dry Needling of the Lateral Pterygoid Muscle

The proposed needle approximation is based on anatomical characteristics of the lateral pterygoid muscle, and it has been clinically applied by the authors for more than 10 years. For this approach, sterile stainless steel

needles with a plastic cylindrical guide, 50 to 60 mm in length and 0.32-mm caliber, are recommended.

The patient is side lying with the mouth opened 10 to 15 mm. For the superior (sphenoid) head, the needle should be inserted over the zygomatic process just posterior at the obituary arch. The needle is advanced from an anterior to posterior direction with an angle of 45° with the horizontal and from a lateral to medial direction with an angle of 15° to the anterior border of the temporomandibular joint. For the inferior (pterygoid) head, the needle is inserted below the zygomatic process just between the mandibular condyle and the coronoid process. The needle is advanced from anterior to posterior and in an upward direction with an angle of 15° to the anterior border of the mandibular condyle (Fig 1, right image). These positions of the needles will theoretically permit the needles to reach both heads of the lateral pterygoid muscle (Fig 1, left image). Figures 2 and 3 show the application of the dry needling approach on real patients.

Anatomical Study

Two heads were removed from 2 fresh male cadavers 65 years of age, which were preserved in a mixture of formalin, alcohol, and Lysoformin. Dissection was conducted by a medical maxillofacial surgeon with more than 20 years of experience at the Anatomy Laboratory of Universidad San Pablo CEU, Madrid (Spain).

First, the dry needling approach of the lateral pterygoid muscle was performed on the fresh cadaver. All the skin and superficial fascia of the posterior part of the temporalis muscle were removed. Second, a block containing the lateral pterygoid was harvested with the following limits: (A) superior: 2 cm above the zygomatic arch; (B) inferior: 2 cm under the coronoid process; (C) posterior: a vertical line behind the external acoustic meatus; (D) anterior: 5 cm anterior to the lateral pterygoid muscle insertion. The dissection was conducted with needles inserted into the head of the cadaver. During the removal of the tissue blocks, care was taken to ensure that dissection did not damage the surrounding tissues with the aim to expose the lateral pterygoid muscle. Finally, a deeper dissection was conducted as follows. The superficial structures including the parotid gland and duct and the masseter muscle were removed. The ramus of the mandible was sectioned by osteotomy to clearly visualize the lateral pterygoid muscle (Fig 4).

RESULTS

The progressive dissection was performed in 3 stages. First, needling approach of the lateral pterygoid muscle was performed on the fresh cadaver (Fig 5). Second, with the needles inserted into the fresh cadaver, the block dissection was conducted to determine if they were inserted into the

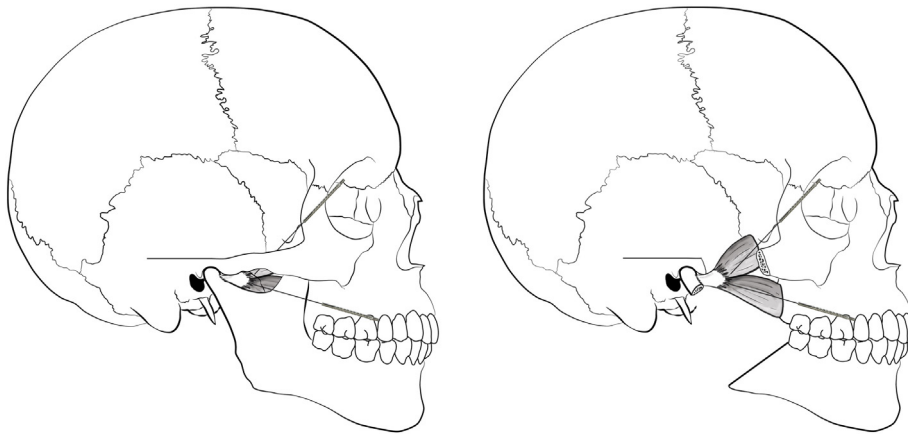


Fig 1. Representation of the dry needling approach of the lateral pterygoid muscle over a cranium with (left image) and without (right image) the zygomatic bone.

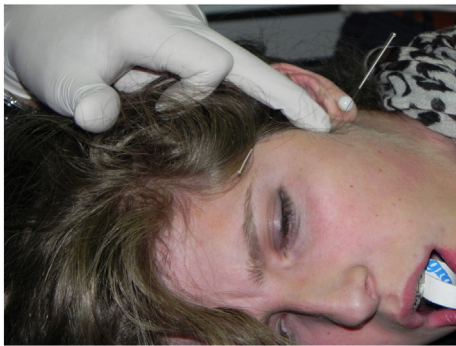

Fig 2. Dry needling of the lateral pterygoid muscle on a patient (lateral view). (Color version of figure is available online).

lateral pterygoid muscle. Figure 6 shows that the superior needle reached the superior (sphenoid) head of the lateral pterygoid muscle, whereas the inferior needle reached the inferior (pterygoid) head of the muscle. At the third and final stage of the dissection, when the ramus of the mandible was sectioned by osteotomy, the superior needle was clearly observed in the muscle belly of the superior (sphenoid) head of the lateral pterygoid muscle (Fig 7).

DISCUSSION

Proper management of patients with TMD includes different interventions such as mobilization techniques, soft tissue techniques, or exercises.¹³ In fact, soft tissues can be treated with manual therapies or dry needling.¹⁴ A recent meta-analysis concluded that trigger point dry needling obtained grade A of effectiveness for decreasing pain immediately after treatment and at a 4-week follow-up in patients with upper quadrant pain syndromes including

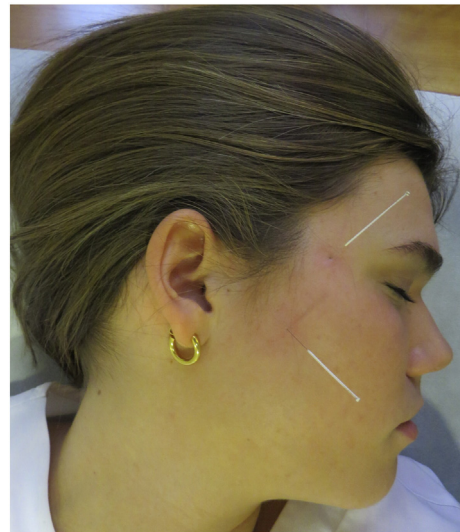

Fig 3. Dry needling of the lateral pterygoid muscle on a patient (superior view). (Color version of figure is available online).

TMD.¹⁵ Therefore, proper approaches for trigger point dry needling of the masticatory muscles are clearly needed.

Several studies have claimed that the lateral pterygoid muscle has a role in the development of TMD, particularly in relation to anterior disk displacement.^{6,7} In fact, some clinical trials have suggested that dry needling of this muscle is effective for the management of temporomandibular pain.¹⁰⁻¹² However, the anatomical location of the lateral pterygoid creates doubt about the proper access to the muscle. The current cadaveric anatomical study supports that dry needling of the lateral pterygoid muscle can be properly performed with the proposed approach. This is clinically important as some authors claimed that the

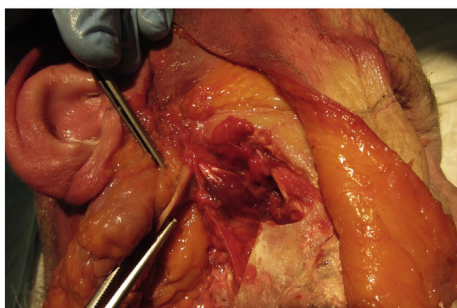


Fig 4. View of the lateral pterygoid muscle after removing the ramus of the mandible by osteotomy on a fresh cadaver. (Color version of figure is available online).

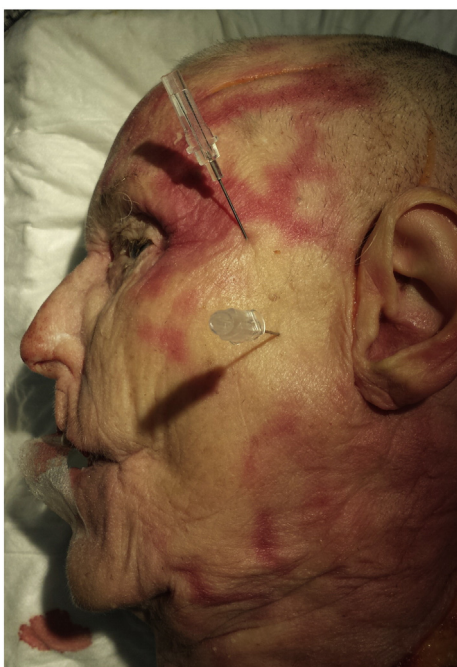

Fig 5. Dry needling of the lateral pterygoid muscle on a fresh cadaver. (Color version of figure is available online).

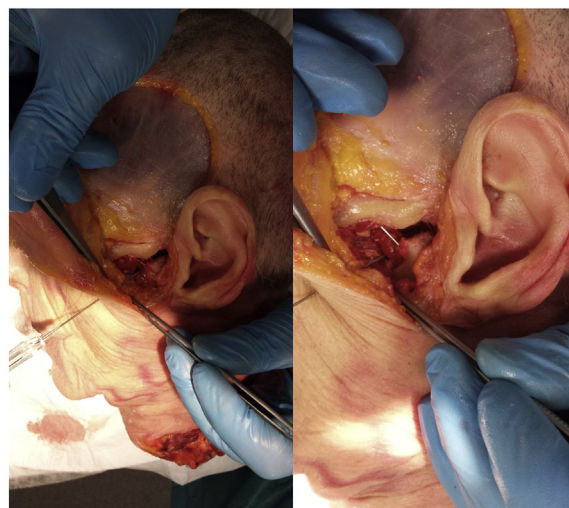


Fig 6. Block dissection of a fresh cadaver's head showing the needles properly reached both the superior (sphenoid) and inferior (pterygoid) heads of the lateral pterygoid muscle. (Color version of figure is available online).

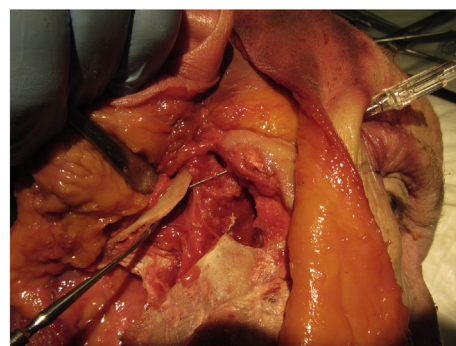


Fig 7. Dry needling of the superior (sphenoid) head of the lateral pterygoid muscle on a fresh cadaver after removing the ramus of the mandible. (Color version of figure is available online).

lateral pterygoid muscle is not accessible to manual palpation^{8,9}; therefore, dry needling may represent the proper therapeutic approach for management of TMD.

The current study described a dry needling procedure for the lateral pterygoid muscle in cadavers. For living patients, the risk inherent to this dry needling approach seems to be low, at least in the clinical experience of the authors; however, some precautions should be considered. Caution should be considered for avoiding needling the temporalis artery with the needle targeted to the superior (sphenoid) head of the muscle; however, this is unlikely because the temporalis artery is more than 5 cm cranially to the zygomatic bone. The needle targeted to the inferior (pterygoid) head of the muscle should be introduced with

caution to avoid excessive penetration of the needle into the infratemporal fossa.¹⁶

LIMITATIONS

Finally, although this study confirmed important and relevant findings related to the lateral pterygoid muscle, we should recognize some limitations. First, the dissection was only conducted in 2 single male cadavers. Some variations in the lateral pterygoid muscle have been described¹⁻⁵; however, it is our impression that these variations would not alter the current findings. Therefore, although promising, current results should be considered with caution. Second,

this article does not determine the effectiveness of the proposed dry needling approach. Future randomized controlled trials should include this new approach for the management of the lateral pterygoid muscle to further determine its clinical effectiveness.

CONCLUSION

This anatomical study supports that dry needling technique of the lateral pterygoid muscle can be properly performed with steel needles of 50 to 60 mm in length. For the superior head, the needle is inserted over the zygomatic process posterior at the obituary arch and is advanced from an anterior to posterior direction with an angle of 45° with the horizontal and from a lateral to medial direction with an angle of 15° to the anterior border of the temporomandibular joint. For the inferior head of the muscle, the needle is inserted below the zygomatic process between the mandibular condyle and the coronoid process and is advanced from an anterior to posterior and in an upward direction with an angle of 15° to the anterior border of the mandibular condyle.

FUNDING SOURCES AND POTENTIAL CONFLICTS OF INTEREST

No funding sources or conflicts of interest were reported for this study.

CONTRIBUTORSHIP INFORMATION

Concept development (provided idea for the research): J.A.M.J., J.S.G., J.L.dl.H.A., C.F.dl.P.

Design (planned the methods to generate the results): J.A.M.J., J.S.G., J.L.dl.H.A., C.F.dl.P.

Supervision (provided oversight, responsible for organization and implementation, writing of the manuscript): J.L.dl.H.A., C.F.dl.P.

Data collection/processing (responsible for experiments, patient management, organization, or reporting data): J.A.M.J., J.S.G.

Analysis/interpretation (responsible for statistical analysis, evaluation, and presentation of the results): J.A.M.J., J.S.G., C.F.dl.P.

Literature search (performed the literature search): J.A.M.J., J.S.G., J.L.dl.H.A., C.F.dl.P.

Writing (responsible for writing a substantive part of the manuscript): J.A.M.J., J.S.G., J.L.dl.H.A., C.F.dl.P.

Critical review (revised manuscript for intellectual content, this does not relate to spelling and grammar checking): J.A.M.J., J.S.G., J.L.dl.H.A., C.F.dl.P.

Practical Applications

- This anatomical study shows the anatomical validation of dry needling of the lateral pterygoid muscle.
- For the superior head, the needle is inserted over the zygomatic process posterior at the obituary arch and is advanced from an anterior to posterior direction with an angle of 45° with the horizontal and from a lateral to medial direction with an angle of 15° to the anterior border of the temporomandibular joint.
- For the inferior head of the muscle, the needle is inserted below the zygomatic process between the mandibular condyle and the coronoid process and is advanced from an anterior to posterior and in an upward direction with an angle of 15° to the anterior border of the mandibular condyle.

REFERENCES

1. Bittar GT, Bibb CA, Pullinger AG. Histologic characteristics of the lateral pterygoid muscle insertion to the temporomandibular joint. *J Orofac Pain* 1994;8:243-9.
2. Usui A, Akita K, Yamaguchi K. An anatomic study of the divisions of the lateral pterygoid muscle based on the findings of the origins and insertions. *Surg Radiol Anat* 2008;30:327-33.
3. Bertilsson O, Ström D. A literature survey of a hundred years of anatomic and functional lateral pterygoid muscle research. *J Orofac Pain* 1995;9:17-23.
4. Heylings DJ, Nielsen IL, McNeill C. Lateral pterygoid muscle and the temporo-mandibular disc. *J Orofac Pain* 1995;9:9-16.
5. Taskaya-Yilmaz N, Ceylan G, Incesu L, Muglali M. A possible etiology of the internal derangement of the temporomandibular joint based on the MRI observations of the lateral pterygoid muscle. *Surg Radiol Anat* 2005;27:19-24.
6. Fujita S, Iizuka T, Dauber W. Variation of heads of lateral pterygoid muscle and morphology of articular disc of human temporomandibular joint—anatomical and histological analysis. *J Oral Rehabil* 2001;28:560-71.
7. D'Ippolito SM, Borri Wolosker AM, D'Ippolito G, Herbert de Souza B, Fenyo-Pereira M. Evaluation of the lateral pterygoid muscle using magnetic resonance imaging. *Dentomaxillofac Radiol* 2010;39:494-500.
8. Stratmann U, Mokrys K, Meyer U, Kleinheinz J. Clinical anatomy and palpability of the inferior lateral pterygoid muscle. *J Prosthet Dent* 2000;83:548-554.
9. Turp JC, Minagi S. Palpation of the lateral pterygoid region in TMD: where is the evidence? *J Dent* 2001;29:475-83.
10. Dıraçoğlu D, Vural M, Karan A, Aksoy C. Effectiveness of dry needling for the treatment of temporomandibular myofascial pain: a double-blind, randomized, placebo controlled study. *J Back Musculoskelet Rehabil* 2012;25:285-90.

11. Itoh K, Asai S, Ohyabu H, Imai K, Kitakoji H. Effects of trigger point acupuncture treatment on temporomandibular disorders: a preliminary randomized clinical trial. *J Acupunct Meridian Stud* 2012;5:57-62.
12. Gonzalez-Perez LM, Infante-Cossio P, Granados-Núñez M, Urresti-Lopez FJ. Treatment of temporomandibular myofascial pain with deep dry needling. *Med Oral Patol Oral Cir Bucal* 2012;17:781-5.
13. Brantingham JW, Cassa TK, Bonnefin D, et al. Manipulative and multimodal therapy for upper extremity and temporomandibular disorders: a systematic review. *J Manipulative Physiol Ther* 2013;36:143-201.
14. Dommerholt J, Fernandez-de-las Peñas C. Trigger point dry needling: an evidence and clinical- based approach. 1st ed. London: Churchill Livingstone: Elsevier; 2013.
15. Kietrys DM, Palombaro KM, Azzaretto E, Hubler R, Schaller B, Schlusell JM, Tucker M. Effectiveness of dry needling for upper quarter myofascial pain: a systematic review and meta-analysis. *J Orthop Sports Phys Ther* 2013; 43:620-34.
16. Vanneuville G, Birou G, Deloup P, Guillot M, Boissier A, Garcier J. The anatomical basis for ultrasonography of the lateral pterygoid muscle and the infratemporal fossa. *Surg Radiol Anat* 1994;16:57-61.